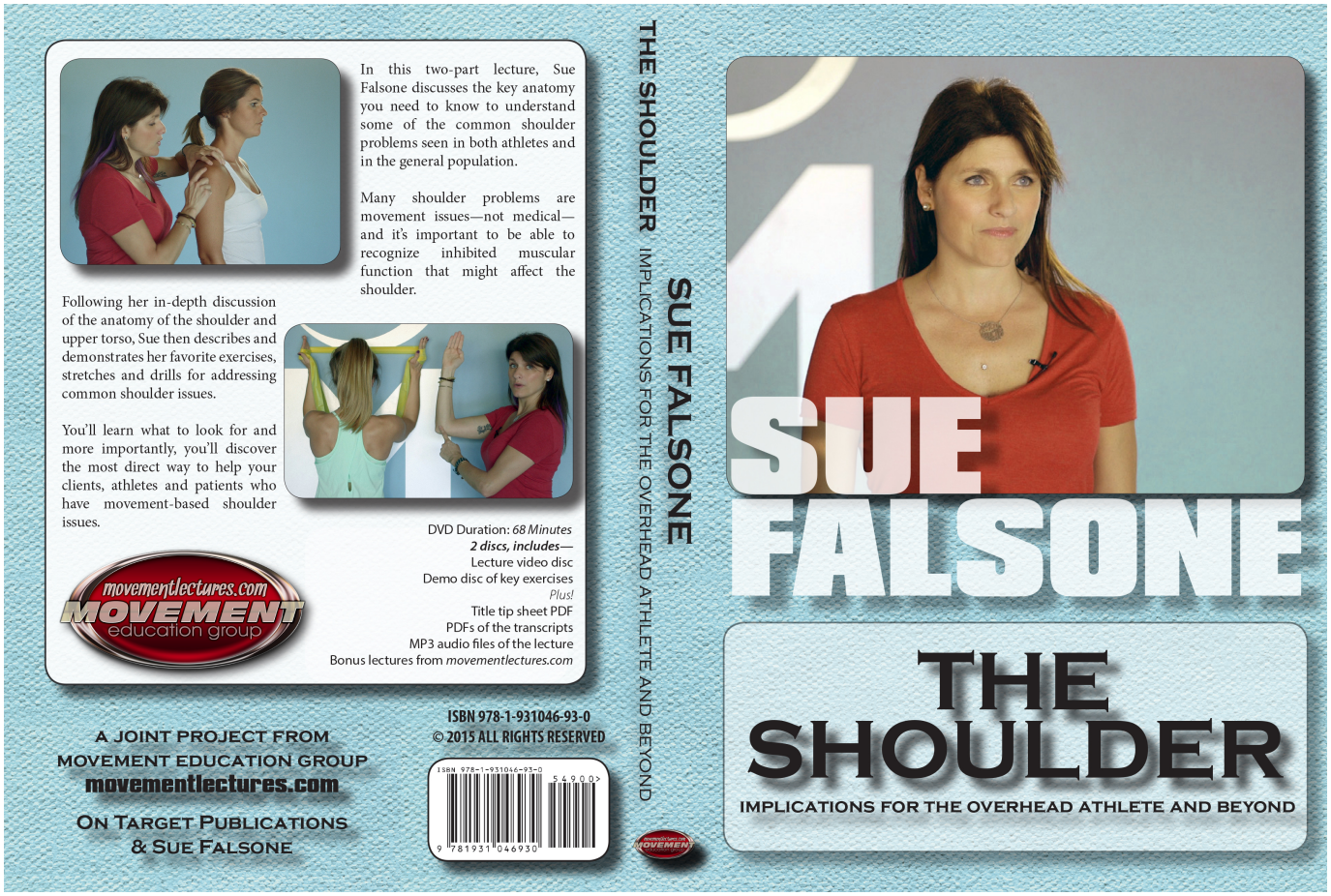

SUE FALSONE

The houlder: Implications for the Overhead Athlete and Beyond
Disc One of Two

This transcript has been edited for smoother reading.
Editorial decisions were made to retain Sue's meaning while converting the live lecture format to text.
For more information on this lecture DVD, please visit
movementlectures.com or otpbooks.com.

I'm Sue Falsone. We're here at the amazing Madison Improvement Club in Phoenix, Arizona. I'm going to be talking about the nature of shoulder injuries—we're going to start off with the anatomy of the shoulde .

When we're talking about athletes with shoulder issues, we're not just looking at the shoulder. Even though that's obviously an incredibly important part of what we're dealing with in the overhead athlete, it's really about how the entire system works together.

Often, the problems showing up at an athlete's shoulder are really stemming from problems that are coming from somewhere in the lower extremity, whether it's poor power development in the legs, or a weak trunk—some type of energy leak somewhere throughout the system.

Even though we're going to be focusing on the shoulder right now, I want you to keep in mind this is just one small part of the system. We really have to look at the entire athlete from top to bottom to figu e out the cause of the shoulder pain, and not just look at the shoulder as one individual part.

To help me today I have my friend Lindsay Whipple. I'm going to have Lindsay come on over and have a seat.

We're going to start by looking at the anatomy of the shoulder. When we're talking about the shoulder as an entire complex, we're really looking at four diffe ent things.

We're looking at the scapulothoracic joint and how the shoulder blade relates to the thoracic spine. We are looking at the glenohumeral joint, which is how the humerus and the humeral head of the shoulder interact with the scapula. We're looking at the AC joint, as well as the SC joint, which is here up front. We really need to look at all four of these joints when we're talking about the shoulder.

Go ahead and stand up, Lindsay.

The shoulder is the most dynamic joint in the body, which is why it's so exciting for me and one of my favorite areas in the body to treat. It's so dynamic. This area from where the clavicle and the spine of the scapula and the acromion meet, between this area, the AC joint, and the humeral head of the shoulder, we have a small space called the subacromial space.

The subacromial space is so small. It's tiny. When you get to see that live in a cadaver, it's amazing how tiny that space is. Anything we have there, whether it is an inflamed tendon or a bone spur or even just poor posture, it doesn't take much to decrease the space we have in that area. When that space gets decreased, we end up with some shoulder impingement and that can be a problem for a lot of athletes.

Okay, go ahead and sit back down, Lindsay.

The first thing we're going to look at is the latissimus. For those of you who have seen me speak before, you know the latissimus is ranking as my second favorite muscle in the body. The diaphragm has taken over as my first favorite muscle in the body, but the latissimus is a strong second and I'll tell you why. It is such an incredible muscle.

The latissimus dorsi actually attaches at the iliac crest and crosses the entire area. The e's a little tip of it that goes over the inferior angle of the scapula, dives underneath the arm and attaches into the front part of the humerus. Tha 's an incredible muscle. We have such a large area here to cover and if you need a reason to believe the hips are just as important as the shoulder, especially with the throwing athlete, it's the latissimus.

The other group of muscles that are very important when we talk about the shoulder is something we call the scapular stabilizers. When we talk about the scapular stabilizers, that's a bit of a misnomer. Nothing about the scapula is truly meant to be stable. If the scapula were meant to be stable, it would have a much better bony connection, but it doesn't have a great bony connection to the body. It has an incredibly expansive muscular connection to the body.

When we talk about the scapula, we need to think of it in terms of controlled mobility—not necessarily stability. I use the term, "scapular stability," as that's a term we all commonly use, but I want you to think about it as really controlled mobility.

The muscles in this area that focus on controlled mobility of the scapula include the trapezius, specifically the lower trapezius muscle, which lies right around here. We also have the middle trapezius and the upper trapezius. This is really all one big, fan-shaped muscle with fibers coming in diffe ent directions. The trapezius is an extremely important muscle group when we're talking about the shoulder.

We also have the rhomboids. The rhomboids lay in this direction, attaching themselves onto the medial border of the scapula right to the center of the spine.

Go ahead and stand up, Lindsay. Face in that direction for me. Go ahead and lift this arm up just a tad.

Another really important muscle for us when we look at the shoulder is the serratus anterior. That serratus actually attaches underneath the scapula, attaches onto the medial border here, runs underneath between the shoulder blade and the ribcage, and attaches down here onto the ribs. The serratus anterior is such an important muscle because it is what keeps the scapula attached to the thorax, so this thing doesn't come winging out.

Bring that down. Go ahead and turn around. Go ahead and put your hands behind your back.

You can see here Lindsay gets a little bit of medial border winging. Often when we see this compensation of medial border winging, it's because the serratus anterior may not be working properly. The serratus anterior is really what keeps this shoulder blade flat against the thorax.

Along with the serratus anterior, we have the rotator cuff. Everybody has heard of the rotator cuff. Keep in mind this group is really four diffe ent muscles. The rotator cuff is made up of the teres minor, which is right around here. We've got the infraspinatus, the supraspinatus and we've got the subscapularis up front.

These four muscles work together to externally rotate and internally rotate the shoulder. Yes, they definitely do that. However, as a group, these four muscles really work well together in order to centrate the humeral head.

As we raise our arm up and down, the rotator cuff works together as a group to keep the humeral head centrated within the joint. If we lose that centration, we get some extra mobility of the humeral head within the joint, and that begins to pinch some of the structures around it.

When that happens, we pinch things over and over and over again. Things get irritated. Tha 's how we develop tendonitises and that's how we develop bursitises. The rotator cuff working together as a group is really important for healthy shoulder function.

Another thing I want to speak about is the diffe ent myofascial slings we have within the body. As we start to look at how these muscle fibers and everything is connected together—for example, we have the rhomboids that run in this direction. Those a e consistent with the fibers of the serratus anterio .

Those serratus anterior muscle fibers come down this way and attach onto the ribs. If we continue to follow those muscle fibers, we have them be continuous with the external obliques. Those obliques come down and attach onto the pelvis.

We know the transverse abdominis muscle fibers run more in this direction. We have these transverse muscle fibers that run around to here and attach toward the very posterior aspect of the back. We have this sling that kind of goes around us that way.

We also have the muscle fibers of the rectus abdominis, which starts at the ribs and goes straight down to the pelvic bone. Supporting the pelvis, we have all of the pelvic musculature of the pelvic floo . On top of that, we have the diaphragm. Actually, the crus of the diaphragm go all the way down to L-1 and L-2.

From a fascial standpoint, they go all the way down toward the sacrum, so we have attachments from the pelvic floor fascially to that diaphragm. The diaphragm comes all the way up to the dome, which sits at about T-6 and re-attaches into the front part of our ribs, so we have a huge sling going this way, as well.

When we want to do some type of intervention, it's going to be really difficul to do something isolative. The e's not much isolative work we can do in the body. We may focus on one area of the body more than another, but everything is so connected that it's difficul to only work one area, and we really see that through the myofascial slings.

Sit back down, Lindsay.

Here are some other things to consider when talking about the shoulder. The shoulder begins to have adaptations to it, especially if we start throwing at a very young age. That old saying "you throw like a girl," which I do, is true because I don't have the physical adaptation of my humerus in order to throw properly.

When we start throwing at a very young age, we start to get some torsion of our humeral head on the shaft of our humerus. This is called humeral retroversion. When we have that retroversion, we allow ourselves to get some more external rotation. Tha 's a necessary skeletal adaptation needed for somebody to throw properly.

We've done some recent studies that were published in *The American Journal of Sports Medicine* in 2013 where we looked at healthy baseball players. We looked at the adaptations at the hip and saw there were no specific adaptation changes at the hip.

Even though we may see specific skeletal adaptations at the shoulder, as of right now we're not seeing a lot of evidence for that at the hip. When we're assessing overhead athletes, specifically baseball players' hips, we may want to be looking at symmetrical range of motion there, but there's a lot more research to be looked at in that area.

I want to speak a little bit about posture. Why is the postural assessment so important for us? In order to know where we are going, we need to know where we are starting. Posture allows us to begin to assess that. Before we can assess somebody's movement patterns, we have to be able to assess static posture.

This gives us a picture of where they're starting from, and we can get a better idea of where they're going to go based on how they're standing and holding themselves.

Sherrington said it best in 1906, "Posture follows movement like a shadow." When we're assessing movement, we absolutely have to start with posture.

The other person who taught us a lot about posture was Vladimir Janda. He was a physiatrist from the Czech Republic and if you haven't read any of his work, I encourage you to do that. He's the person who developed what's called the "Upper Crossed Syndrome" and the "Lower Crossed Syndrome."

What these Upper and Lower Crossed syndromes allow us to begin to package these things together. We see common compensatory patterns. Just like we do in movement inefficien , we see them in posture as well. We can begin to bundle these compensations together to help us with our evaluation and begin to set a guide as we learn the study of postural assessment.

The first thing e're going to look at is the Upper Crossed Syndrome.

Lindsay, I'm going to have you swing your legs around there. She's got pretty good posture right now.

What we typically see in the Upper Crossed Syndrome is a protruded head. The body doesn't want to look downward all day—we wouldn't be able to walk around. We wouldn't be able to get our jobs done.

When we slump like this, with the natural tendency for our head to look down, we can't function this way throughout the day. So what do we have to do? We have to level our eyes. That way, we can go about our activities.

Here the chin gets jutted forward. We place a lot of stress on the TMJ. We start to get some shortening of the cervical paraspinals of the suboccipital muscles. We get lengthening of these deep neck fle ors and they begin to not work well any more.

We get a rounding of the shoulders, which gives a tightening or shortening of the pectoralis musculature. We get a lengthening of our periscapular musculature, so the scapular stabilizers no longer are in a great length-tension relationship to manage what the scapula is doing. We begin to get some upper thoracic dysfunction and some cervical-thoracic dysfunction issues, as well.

These are just common things we are able to bundle together. When you have an athlete or a patient walk into your offic and you see this type of pattern, you can begin to look at these types of things and see if there are weaknesses here, if there are shortenings in the areas we talked about. It kind of gives us a little bit of a grouping and a pattern to work with.

Go ahead and stand up, Lindsay. Face that direction.

This is going to probably be a little bit difficul for Lindsay to demonstrate, but when we look at the lower back, Vladimir Janda described for us a Lower Crossed Syndrome. What the Lower Crossed Syndrome is—and it's going to be difficul for her to demonstrate that—but it's when we get this anterior tilt of the pelvis.

We see this often, especially in larger offensi e linemen football players who have a big anterior tilt in the pelvis. They begin to get these big sausage paraspinals because the paraspinals of the low back are working so hard, they get really hypertrophied.

We get tightness in the front part of the hips, so the hip fle ors begin to get really short. We begin to get what some people call "glute amnesia." Because the glutes are in a poor position due to the position of the pelvis, it's more difficul for the gluteal musculature to fi e.

The glutes are so important for our athletes. Tha 's where they develop their power. Tha 's where they begin to develop that drive from the ground, and transfer that energy through the body. If they're not able to develop that power because of this position in the pelvis, their throwing shoulder is going to be dead in the water even before they begin.

Even though everybody doesn't necessarily present with these two types of syndromes, they are very common and do give us a place to start.

When we begin to talk about ideal alignment, what is that? How do we define that?

Ideal alignment is so diffe ent for everybody, but really Pavel Kolar described it best. He described it to me as a co-activation—a simple co-activation of our internal and external rotators, our abductors and adductors, and our extensors and our fle ors. When we have this perfect co-activation, the body is in a great state of homeostasis. Nothing is working too hard.

If we take a plumb line down and look at alignment, the ear should be right over the shoulder. The shoulder is right over the hips. The hip is right through the knees. The knees are right through the ankle. We should see this nice, straight line. What often happens is we get an overtaking of what he describes as "the old system."

Go ahead and slouch for me.

Tha 's a typical slouched posture. That typical posture we see, not only in our athletes, but in our patients and in everyday life—that tired… everything is sort of just hanging on the ligaments' posture. He describes that as "the old system" is taking over.

When we think about the old system, think about back to the way we're born. When a baby is born, it's in this little ball, all curled up. It's not until they begin to hear their mom's voice or their eye catches something shiny or they hear a noise behind them that they begin to pick up their head, and they begin to lift up, and they begin to explore the world around them. When that happens, their extensors start to fi e. Their abductors begin to fi e. Tha 's called "the new system."

Think about it. When you're tired, what do you do? You slouch. When you're afraid, what do you do? You protect yourself. When you hurt yourself, you bring your arm in. If you've known anyone to have a stroke, what happens? They get that internally rotated position. People with cerebral palsy, it's the same thing. They get into that internally adducted position.

Everything that happens to us, whether it's neurological, biomechanical or emotional, it all takes us back to that old system. Tha 's why so many of our interventions have to focus on the new system.

Tha 's not to say we never focus on a pattern of flexion, internal rotation and adduction. It's just that often in our interventions we need to spend more time on the new system. We need to spend more time on our external rotators, abductors and extensors in order to combat that very embedded need for us to go back to the old-system position.

Go ahead and have a seat, Lindsay.

Now, I'm going to have her sit up very tall.

Lindsay, all I'm going to have you do is to think about flattening out your back and just relaxing your low back for me. The e we go. Then, sit back up nice and tall. Do that again, and sit up nice and tall.

What I want you to recognize is as that happens, she's only thinking about slouching her low back, but look at what happens to her head. Her head comes jutting forward. Her thoracic spine begins to round. If she corrects the position of her low back, her shoulders come back up over her pelvis. Her head comes in a nice alignment with her shoulders again. We're built on these cogwheels where one area of the spine affects anothe .

Going back to the shoulder, the shoulder is attached to the thoracic spine, but we can't just consider the shoulder. We have to consider what else is going on at the low back because it's going to affect the positions above it. If the mid-back gets affected, the neck is going to be affected. If we put stress on these muscles, it's going to be very difficul for the throwing shoulder to be effecti e and efficien

Lindsay, I'm going to have you go back to the corner of the table.

Looking for good alignment for this upper quarter, the first thing we want to look at is the vertebral border or the medial border of the scapula. This should be parallel to the spine of the scapula. If we begin to see some diffe ent rotations…

Go ahead and slouch for me.

…and we see a downward rotation of the shoulder or anything that takes the medial border of the scapula away from being parallel, we know the scapula is probably not in the most efficien position. If it's not in an efficien position, it's going to be very difficul for those muscles to do their jobs.

Go ahead and sit back up tall.

The other thing we want to look at is the spine of the scapula. Tha 's going to be right at around T-4. If we see someone who is extremely elevated or extremely depressed and we are poking around the spine of the scapula and it's not sitting right around T-4, this may give us another indication that something is elevated or depressed.

The scapula should also lie flat against the ribcage. We've already talked about with Lindsay, we see a little bit of a winging here in her scapula. That may not necessarily be an awful thing, but it's something for us to note. If this scapula is not sitting flat against the ribcage, e need to look at some reasons for potentially why.

If we're seeing more of what we call an inferior angle winging when we see more of this area sticking out at us versus an entire medial border angle winging out—those are two diffe ent things. That medial border winging we've already talked about, the serratus is kind of holding that medial border of the shoulder onto the thorax. If it's not able to do that, it's going to begin to wing a little.

The other thing we see with inferior angle winging is what's called an anterior tilt of the scapula. The things attached to the front part of the scapula are pulling the scapula forward, tilting it anteriorally and giving this exaggerated angle at the bottom of the scapula.

That may be because of biceps tightness. That may be because of pec minor tightness. The e could be a lot of different reasons, but we need to recognize that medial border winging and inferior angle winging are two diffe ent things. Right now, we're just noting: Is the scapula lying flat against the thorax

Go ahead, stand up, Lindsay, and turn around.

Another thing to take note of is the SC and the AC joints. The AC joint should be sitting about one inch higher than the SC joint.

Go ahead and depress the shoulder for me.

It's hard for her to do, but if we note the AC joint is more in alignment with the SC joint, the entire shoulder girdle is a little bit depressed. If she's holding her shoulder blade whether because it's painful—we have some weaknesses or tightnesses somewhere—and we notice that the AC joint is significantly higher than the SC joint, this gives us some information. A normal position is just about one inch higher than the SC joint.

The other thing to look at

Go ahead and turn to the side.

…is the position of the humeral head. If we find the AC joint and then we find the position of her humeral head and put our fingers on either side of that, we can determine the position of that humeral head within the shoulder complex.

Ideally, this humeral head is about one-third in front of the AC joint and about two-thirds behind it. When we have somebody where the humeral head is two-thirds in front of the AC joint, we know the humeral head is sitting further anterior in the shoulder joint.

When we're talking about an overhead athlete who needs to get some extreme external rotation in order to throw, we need to help get the humeral head back into that position.

Think about the associated arthrokinematics that go along with external rotation. In order for that to happen, the humeral head needs to roll forward. In these cases where the humeral head is already sitting way far anterior in the shoulder, where does the humeral head have to go?

The e's nowhere left for it to go, so what does it have to do? It has to blow through the labrum. It has to blow through the structure that is there to give the shoulder some stability in order to get more motion.

Tha 's probably one reason why we see so many asymptomatic labral tears in overhead athletes. They need to blow through the labrum in order to compensate for a postural adaptation they've created throughout their lives.

Looking down the arm, ideally, if we're looking from the back, we're able to see the olecranon. If we're looking from the front, we're able to see the palm of the hand a little bit more than the back of the hand.

If you are assessing posture and they're very internally rotated to the point you're looking at the back of the hand if you're standing in front, or if you're behind and you're seeing more of the palm of the hand, we know they're in a more internally rotated position. We want them to be in a little bit more of an externally rotated or at least a neutral position when just standing here in neutral.

The other thing we're going to note is the position of the spine. Are they holding the head significantly forward of the shoulders? Does the ear align with the AC joint? Is it really far forward, is it more backward or is it fairly neutral?

What is the position of the spine? Are we seeing an anterior tilt or a posterior tilt of the lumbar spine? Do we see a flat-ness in the thoracic spine, or do e see a big hump or a big bump in the thoracic spine?

All of those give us diffe ent information. We're not going to break down all of that stuff today. We're just noting it because each individual piece of information doesn't really tell us much. We have to be able to take all of the pieces of information from the posture and put it together in order to begin to solve this puzzle.

One thing to note on the thoracic spine: A lot of us utilize the Functional Movement Screen. I do, and one thing I look at is the shoulder mobility test based on the general range of motion.

If we have an athlete who scores a '1' or a '2' on the Functional Movement Screen and cannot get the hands to touch behind the back, we need to compare that to the range of motion when lying down.

So, go ahead and turn this way, Lindsay. Put your thumbs inside your fists. Bring your arms out for me—one arm up, one arm down.

Ideally, they get within one hand's length of each other.

Go ahead and go the other direction.

So, maybe there's a little bit of a discrepancy.

Rest for me.

Now, if we were to lay her on her back and look at her range of motion, and she's got normal external rotation, she's got normal internal rotation on the table, and yet maybe she has a '1' or a '2' or a major asymmetry in her shoulder mobility test, that tells us something.

That tells us if she's got normal rotation on the table, but a poor shoulder mobility test on the Functional Movement Screen, that has nothing to do with the glenohumeral joint. That has to do with thoracic rotation and thoracic limitations.

Turn around again, Lindsay, and do that motion one more time.

In order to do this motion, we need to have rotation of the thoracic spine. We need to have extension of the thoracic spine.

Rest for me.

If she's got normal rotation at the glenohumeral joint, but yet is unable to do the Functional Movement test of the shoulder mobility, that's typically because of thoracic mobility. We now know this is an area to assess more in depth.

Those of you who know me know I'm a complete anatomy nerd. I love studying anatomy—I love studying everything about it. I love seeing the connections of the diffe ent muscles and diffe ent myofascial connections that are present in the body, and seeing how all that works together.

I encourage you to use diffe ent resources, and really study the anatomy. I think if you know the anatomy and your biomechanics, you can figu e just about anything out.